

Discord between presence of follicular conjunctivitis and *Chlamydia trachomatis* infection in a single Torres Strait Island community

A cross-sectional survey

Lynch, Kathleen D.; Brian, Garry; Ahwang, Tomasina; Newie, Tomi; Newie, Victoria; Perrett, Christine; Wharton, Ghislaine; Brown, Anthony; Tozer, Sarah; Kaldor, John M.; Whop, Lisa J.; Andrews, Ross M.; Lambert, Stephen B.

Published in:
Australian and New Zealand Journal of Public Health

DOI:
[10.1111/1753-6405.13179](https://doi.org/10.1111/1753-6405.13179)

Published: 01/04/2022

Document Version
Publisher's PDF, also known as Version of record

[Link to publication](#)

Citation for published version (APA):

Lynch, K. D., Brian, G., Ahwang, T., Newie, T., Newie, V., Perrett, C., Wharton, G., Brown, A., Tozer, S., Kaldor, J. M., Whop, L. J., Andrews, R. M., & Lambert, S. B. (2022). Discord between presence of follicular conjunctivitis and *Chlamydia trachomatis* infection in a single Torres Strait Island community: A cross-sectional survey. *Australian and New Zealand Journal of Public Health*, 46(2), 155-160. <https://doi.org/10.1111/1753-6405.13179>

General rights

Copyright and moral rights for the publications made accessible in the public portal are retained by the authors and/or other copyright owners and it is a condition of accessing publications that users recognise and abide by the legal requirements associated with these rights.

- Users may download and print one copy of any publication from the public portal for the purpose of private study or research.
- You may not further distribute the material or use it for any profit-making activity or commercial gain
- You may freely distribute the URL identifying the publication in the public portal

Take down policy

If you believe that this document breaches copyright please contact us providing details, and we will remove access to the work immediately and investigate your claim.

Discord between presence of follicular conjunctivitis and *Chlamydia trachomatis* infection in a single Torres Strait Island community: a cross-sectional survey

Kathleen D. Lynch,^{1,2} Garry Brian,^{1,3} Tomasina Ahwang,³ Tomi Newie,³ Victoria Newie,³ Christine Perrett,³ Ghislaine Wharton,^{3,4} Anthony Brown,³ Sarah Tozer,² John M. Kaldor,⁵ Lisa J. Whop,^{6,7} Ross M. Andrews,^{6,7} Stephen B. Lambert^{1,2,7}

Trachoma, caused by ocular infection with specific serovars of the bacterium *Chlamydia trachomatis*, is the world's leading infectious cause of blindness.¹ In communities where trachoma is endemic, children suffer repeated ocular infections with *C. trachomatis*, which presents as a follicular conjunctivitis (trachomatous inflammation – follicular [TF]), often with inflammatory thickening of the upper tarsal conjunctiva (trachomatous inflammation – intense [TI]).^{2,3} In some individuals, years of repeated *C. trachomatis* infections can result in fibrosis and scarring of the upper subtarsal conjunctiva (trachomatous scarring [TS]), leading to in-turning of the eyelashes (trichiasis), abrasion of the cornea and – eventually – irreversible blindness.^{2,3} In 2021, Australia remains the only high-income country with endemic trachoma, and it is found almost exclusively among Aboriginal and Torres Strait Islander peoples, Australia's Indigenous people, in remote communities in Western Australia, South Australia and the Northern Territory.^{1,4} These two groups: Aboriginal people and Torres Strait Islander people, are culturally and linguistically diverse, make up many nations, and continue to experience the ongoing legacy of colonisation, oppression and dispossession, which has resulted in large social disadvantage.

Abstract

Objective: Recent surveys identified trachomatous inflammation – follicular (TF) at endemic levels in the Torres Strait Islands; however, local health staff do not report trachomatous trichiasis (TT) in adults. We undertook a cross-sectional survey involving eye examination and microbiological testing to better understand this disconnect.

Methods: We examined 169 of 207 (82%) residents and collected ocular swabs for polymerase chain reaction (PCR) testing for *Chlamydia trachomatis*. Other viral PCR tests and bacterial culture were also performed.

Results: TF prevalence in children aged 5–9 years was 23% (7/30). No ocular *C. trachomatis* was identified by PCR. For the 72 participants (43%) with follicles, bacterial culture was positive for 11 (15%) individuals. No individual had trachomatous trichiasis.

Conclusions: Follicular conjunctivitis consistent with TF was prevalent but ocular *C. trachomatis* and cicatricial trachoma were absent. Non-chlamydial infections or environmental causes of follicular conjunctivitis may be causing TF in this community.

Implications for public health: In similar settings, reliance on simplified clinical assessment alone may lead to an overestimation of the public health problem posed by trachoma. Consideration should be given to incorporating *C. trachomatis* PCR, and in certain settings, a detailed clinical exam could be performed by an experienced ophthalmologist during prevalence surveys.

Key words: trachoma; ocular *Chlamydia trachomatis*; chlamydial conjunctivitis; Queensland; neglected tropical disease

To eliminate trachoma as a public health problem, Australia's public health guidelines recommend the World Health Organization (WHO) endorsed 'SAFE' strategy: surgery for trichiasis, antibiotic treatment to clear infection, and facial cleanliness and environmental improvement to reduce transmission of ocular *C. trachomatis*.^{5,6}

Improving environmental health aims to address the underlying environmental risk factors for trachoma including inadequate housing and a lack of access to clean and functioning water supplies.⁵ Mass drug administration (MDA) with oral azithromycin for three years is recommended in communities where the prevalence of TF in

1. Communicable Diseases Branch, Prevention Division, Queensland Health

2. UQ Centre for Clinical Research, The University of Queensland

3. Torres and Cape Hospital and Health Service, Queensland

4. Cairns Eye & Laser Centre, Cairns, Queensland

5. The Kirby Institute, University of New South Wales

6. Menzies School of Health Research, Charles Darwin University, Northern Territory

7. National Centre for Epidemiology and Population Health, The Australian National University, Australian Capital Territory

Correspondence to: Ms Kathleen Lynch, Child Health Research Centre, The University of Queensland; e-mail: Kathleen.Lynch1@uqconnect.edu.au

Submitted: March 2021; Revision requested: August 2021; Accepted: September 2021

The authors have stated they have no conflicts of interest.

This is an open access article under the terms of the Creative Commons Attribution-NonCommercial-NoDerivs License, which permits use and distribution in any medium, provided the original work is properly cited, the use is non-commercial and no modifications or adaptations are made.

Aust NZ J Public Health. 2022; 46:155-60; doi: 10.1111/1753-6405.13179

5–9-year-old children is >5–<20%, mass drug administration (MDA) with oral azithromycin is recommended at 0, 12, and 24 months. Where the TF prevalence is >20%, 6 monthly MDA is recommended for two years (total of 5 MDAs – 0,6,12,18 & 24 months).⁵ However, as TF as a clinical sign is not highly specific for trachoma in low prevalence settings, the positive predictive value of TF for ocular *C. trachomatis* is poor at both an individual and community level.^{7,8}

Based on clinical examination alone, cases of TF have historically and recently been reported in the First Nations peoples who reside in the island communities of the Torres Strait (known as Torres Strait Islander people).^{4,9} The Torres Strait is a body of water that separates Far North Queensland and Papua New Guinea where there is strong connectedness to land and country with strong Indigenous leadership. However, from the late 1970s until the present day, no TT or associated CO have been identified or surgery for trachomatous-related trichiasis performed in the Torres Strait.^{9–12}

Trachoma survey work in the Torres Strait has been irregular. In a 2008 survey of one island community, TF was identified at endemic levels (11%) but conjunctival specimens for polymerase chain reaction (PCR) testing were negative for *C. trachomatis*.^{11,13} Given this and the absence of chronic sequelae due to trachoma, no antibiotic treatment was given.¹¹ A follow-up survey in this same untreated community in 2012 did not find any TF.¹¹ In 2012, in a neighbouring community, conjunctival specimens were taken from eight children assessed as having TF and their household contacts (30 individuals); all were PCR negative for *C. trachomatis*.¹¹ Further follow-up studies were undertaken in both communities in 2016 and 2017. Follicular conjunctivitis consistent with trachomatous inflammation – follicular was found at rates exceeding elimination targets, however, all cases were PCR negative for *C. trachomatis* (W. Morotti, Communicable Diseases Branch, Queensland Health, personal communication, February 2021).

The clinical signs of TF are a response to ocular infection with *C. trachomatis* and these may persist longer than it takes for an individual to clear the infection.³ However, at any given point in time, it would be unusual for all cases of TF in a community to be free of *C. trachomatis*, with negative PCR tests, as occurred in the Torres Strait. To date, several studies have begun to examine the

contribution nonchlamydial pathogens may make to a TF-like follicular conjunctivitis.^{14–16} These studies, along with repeated reports of endemic follicular trachoma in the absence of TS or TT over a 40-year period, raised the question as to whether TF in the Torres Strait was related to trachoma or if non-chlamydial pathogens or other causes may be responsible. We aimed to test this hypothesis using a cross-sectional prevalence survey for active trachoma and its long-term sequelae in all community members of one island community.

Methods

Community engagement and approvals

Before conducting research activities, we undertook consultation with and sought consent from community leaders, local clinicians, Aboriginal and Torres Strait Islander health workers, and the Torres Strait Island Regional Council to ensure their support and to seek input into the design of the project. Notification of the research team's visit was also provided to the chair of the relevant Native Title Organisation in line with established cultural protocols. Feedback between the researchers and community was a two-way process occurring throughout all stages of the research journey. Cultural review of the manuscript occurred prior to publication.

Ethics approval was obtained from the Far North Queensland Human Research Ethics Committee (HREC/16/QCH/113 – 1086) and The University of Queensland Human Research Ethics Committee (2017001012/HREC/16/QCH/113-1086). Written informed consent was obtained from each participant 18 years of age or older. For those aged younger than 18 years, written consent was obtained from a parent or guardian, and child assent was obtained where possible.

Initial contact with potential participants was made with a generic letter of invitation provided to each household in the community via a letterbox drop. In the week before data collection, a community event was held to provide information about the project. During the data collection week, another community event was held. A population list was compiled using the medical clinic list and local knowledge of Aboriginal and Torres Strait Islander health workers.

Study design

We conducted a cross-sectional trachoma prevalence study of people present in a selected Torres Strait Island community during a one-week period in November 2017. The selected community is one of five located in the western islands of the Torres Strait. The island group has a resident population of approximately 1,440 people. The community surveyed was selected due to historical and recent reports of TF prevalence $\geq 5\%$, the threshold set in Australia's national guidelines for antibiotic treatment and further screening. While we were unable to control sample size as this study was a single community project, we performed sample size calculations using the single population proportion for precision formula adjusted for a finite population using the following assumptions: an expected proportion of 5%, 10%, 20%, an absolute precision of 2%, and a 95% confidence interval. The resulting sample size suggestions were 143, 168, and 183, respectively.

Clinical assessment

We offered enrolment in the study to all people resident in the community during the research team's visit. Clinical examination was conducted by an ophthalmologist using 2.5 mm x binocular loupes and a torch. Eyes were examined and graded for trachoma using the WHO simplified trachoma grading system and assessed for the presence of corneal pannus and Herbert's pits, recognised signs of trachoma.^{2,7} Prior to the research activity the ophthalmologist undertook and passed the Centre for Eye Research Australia's Trachoma Grading Self Directed Learning program, which is an accepted threshold for training in Australia consistent with practice in other states and territories.¹⁷ Each participant was examined by the ophthalmologist for the presence of a clean face, defined by the national guidelines as the absence of visible nasal and ocular discharge on the face.⁵ To minimise the risk of cross-contamination, hand hygiene was performed by the ophthalmologist and clinical assistant between subjects. Participants found to have ocular pathology were referred by the ophthalmologist to either the local primary health centre or the regional specialist clinic for ongoing care.

Conjunctival sampling

Immediately after clinical examination, two conjunctival specimens were collected from

each eye. A dry sterile cotton swab [P/N: MW104 (Medical Wire & Equipment)] was passed four times across the everted upper tarsal conjunctivae, rotating the swab at 90 degrees after each pass. Swabs were placed into sterile tubes and kept cool and dry before transfer within 24 hours of collection to the local Pathology Queensland laboratory for processing. For those participants found to have any upper tarsal follicles, an additional conjunctival specimen was collected from each eye for bacterial culture and sensitivity testing. For each eye, a single sterile rayon tipped swab (Transystem M40 408C (Copan)) was passed four times across the upper tarsal conjunctivae, rotating the swab at 90 degrees after each pass. Swabs were placed into sterile tubes with a swab medium (Amies transport gel) and kept cool and dry prior to transfer within 24 hours of collection to the local Pathology Queensland laboratory for processing.

Polymerase chain reaction testing

Swabs collected for molecular screening were processed for *C. trachomatis* and *Neisseria gonorrhoea* as per the manufacturer's instructions for the Cobas® Amplicore (CT/NG) kit, and for extended molecular screening by extraction on the Roche MagNA Pure 96 Instrument system using the MagNA Pure 96 DNA and Viral NA Small Volume Kit (Roche, Victoria Australia). DNA extracted from swabs was tested by PCR for gene targets to *C. trachomatis* and *Neisseria gonorrhoea* using the Roche COBAS 480 analyser and the Cobas® Amplicore (CT/NG) kit, (Roche, North Ryde NSW) at Pathology Queensland central laboratory, Brisbane, Queensland (2,200 kilometres from the Torres Strait Islands).

Total nucleic acids were extracted from the second sample with additional PCR testing performed at the Queensland Paediatric Infectious Diseases Laboratory. Testing for viral pathogens known to cause follicular conjunctivitis including adenoviruses, enteroviruses, rhinovirus, herpes simplex viruses type 1 and type 2, cytomegalovirus, and Molluscum contagiosum virus was undertaken using standard methods described elsewhere.^{18–23} Control measures for extraction efficiency and PCR performance were performed using a known quality of equine herpes virus that was spiked to each of the samples extracted and tested using a method described elsewhere.²⁴

Bacterial culture

Organisms for identification and antimicrobial susceptibility testing included *Staphylococcus aureus*, *Haemophilus influenzae*, *Streptococcus pneumoniae*, *Pseudomonas aeruginosa*, *Moraxella catarrhalis*, *Neisseria gonorrhoeae*, *Neisseria meningitidis*, *Corynebacterium macginleyi*, as well as pure growth of Gram-negative enteric organisms. Isolates were identified using the VitekMS instrument and antimicrobial susceptibility testing was performed using the Vitek2 system for non-fastidious isolates or by EUCAST disc diffusion methods for fastidious organisms.²⁵ Beta-lactamase testing was performed on *Haemophilus influenzae*, *Moraxella catarrhalis* and *Neisseria* isolates using the nitrocefin method.²⁶

Data recording and analysis

We performed descriptive epidemiological assessments of the data in Microsoft Excel. This included assessing counts and percentages for the presence of clinical features, and the identification of *C. trachomatis* and other pathogens by age group.

Results

Study population

Of 207 adults and children aged 1 year or older who were residents in the community, we enrolled 169 people (82%) into the study (Table 1). Our population coverage in the 5–9 years age group (91%) was considerably higher than the 85% coverage required for trachoma surveys by the national guidelines (Table 1).⁵ Nearly all participants (159, 94%) identified as being of Indigenous origin; 73% (123/169) identified as Torres Strait Islander but not Aboriginal origin, 4% (7/169) as Aboriginal but not Torres Strait Islander origin, 17% (29/169) as both Aboriginal and Torres Strait Islander origin, and 6% (10/169) as neither Aboriginal nor Torres Strait Islander origin. The age of participants ranged from 1 to 80 years, with median 29 years; 53% were female. Cases of follicular conjunctivitis were evenly distributed between males and females. We were unable to collect data on the reason for the refusal.

Clinical examination

Prevalence of TF according to the simplified WHO grading system was 23% among 30 children aged 5–9 years (Figure 1). Prevalence was 13% among 15 children aged 1–4 years and 20% (9/45) among children aged 1–9 years. No participant had TS, TT, or Herbert's pits. A single participant, aged older than 60 years, had unilateral corneal pannus and TI, but no other clinical signs that might be attributed to trachoma. All individuals screened for trachoma were also assessed for facial cleanliness. The overall prevalence of clean faces in children aged 5–9 years was 87% (26/30 [Figure 1]). Prevalence was 67% among 15 children aged 1–4 years and 80% (36/45) among children aged 1–9 years.

Polymerase chain reaction testing

Conjunctival swabs for PCR testing were collected from 100% of individuals enrolled in the study. No *C. trachomatis* was found by PCR in any of the participants and there were no positive PCR results for other pathogens.

Bacterial culture

Conjunctival swabs were collected from 71 of the 72 individuals (99%) found to have TF or any tarsal follicles on clinical examination (Figure 1). One child in the 1–4 years age group did not tolerate collection of specimens for bacterial culture in either eye and one child in the 5–9 years age group tolerated collection in one eye only. Swabs from 11 (15%) individuals grew one or more organisms (Table 2)

Discussion

In this community-wide trachoma survey in the Torres Strait, we found follicular conjunctivitis consistent with TF to be highly prevalent. According to current Australian guidelines, the prevalence of TF we identified in 5–9-year-olds (23% [7/30]) suggests trachoma is a public health problem in this community and public health intervention, including community-wide mass drug administration with azithromycin is recommended six-monthly for two years.⁵

Table 1: Percentage of the population who were enrolled into the cross-sectional trachoma survey presented by age group, Torres Strait Islands, November 2017.

Age	1–4 years n=18	5–9 years n=33	10–14 years n=22	15+ years n=134	All age groups n = 207
Population coverage	15 (83%)	30 (91%)	22 (100%)	102 (76%)	169 (82%)

Here, we undertook further investigation and demonstrated that no individual with follicular conjunctivitis consistent with TF, nor any other individual surveyed had ocular *C. trachomatis* present at the time of the survey.

In areas where trachoma is endemic, TI, a manifestation of severe active trachoma, is common among young children, and when repeatedly present over prolonged periods of observation, is the best-known predictor of TF in adults.²⁷ Herbert's pits are pathognomonic of past trachomatous inflammation, corneal pannus is frequently present (unlike follicles, rarely occurs independently of other signs of trachoma), most adults have some degree of TS, and TT is present in adults at levels >0.2%.^{3,6,7,28} We found an absence of TI in children in this survey, consistent with findings in previous surveys from 2008–2017.

We did not identify Herbert's pits or any form of cicatricial trachoma. There was a single case of unilateral TI and corneal pannus in an adult. We demonstrated that TT, TS, and CO is absent in this community, and this is consistent with the experience of local health professionals who report a 25-year absence of the long-term complications of endemic trachoma in the Torres Strait.¹¹ The results from bacterial culture did not identify a plausible cause for the follicular reactions (Table 2).

The high prevalence of TF, together with the absence of TI in children and lack of TT in adults, paints a conflicting clinical picture of the public health threat posed by trachoma in this community. The valuable insights gained through laboratory testing and detailed clinical examination performed by an ophthalmologist suggests that trachoma

is not a public health problem in this community. The findings of our study add to the growing body of evidence suggesting that in settings where there are high rates of TF and low rates of TT, programmatic decision-making should not rely solely on the prevalence of clinical signs identified using the WHO simplified grading system.^{15,16,29,30} The results reported in this paper have been reviewed by Australia's national Trachoma Surveillance and Control Reference Group.

Our findings occur in the context of a historical lack of vision-threatening trachoma pathology in a tropical community with good sanitation, reticulated water, and a facial cleanliness prevalence in children aged 5–9 years that exceeds the national guidelines target of 85%.^{4,9–11} Taken together, our results suggest that while follicular conjunctivitis consistent with TF is hyperendemic, the cause is not ocular *C. trachomatis* and residents of this island community are not at risk of blindness from trachoma. Given this, adherence to Australia's national guidelines would involve unnecessary public health intervention with inappropriate antibiotic administration and significant financial implications.

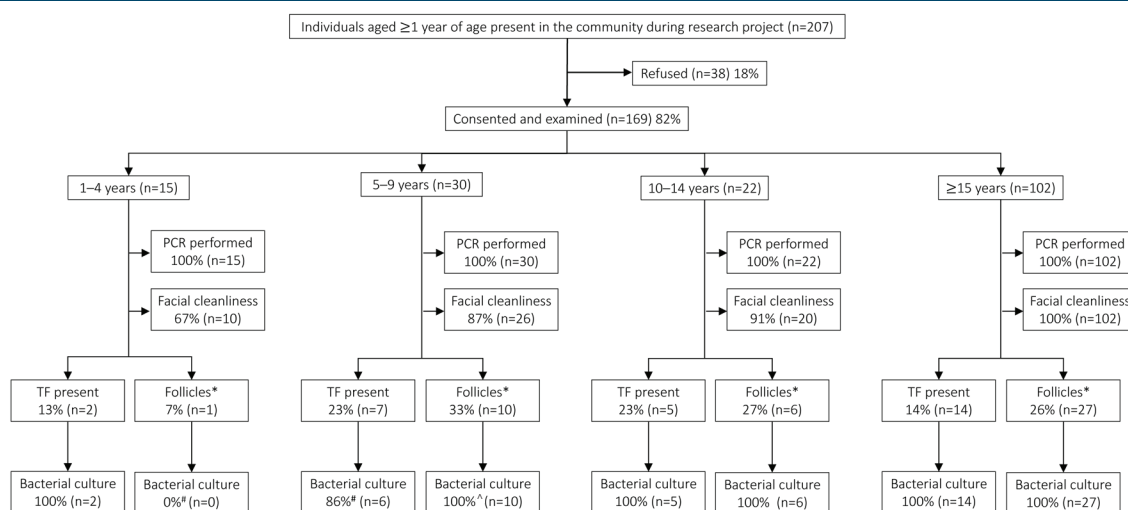
While this investigation is limited by the small study size and single location, our findings align with those from a historical survey undertaken in the Torres Strait Islands in 1982 that found follicular conjunctivitis prevalent among children and an almost total absence of cicatricial trachoma in adults.¹² In the Torres Strait, the absence of *C. trachomatis*

Table 2: Cases of bacterial infection in individuals with 1–4 follicles in either eye, with trachomatous inflammation—follicular (TF) in either eye, and without either follicles or TF in either eye, Torres Strait Islands, November 2017.

Organism	Individuals with 1–4 follicles (n=44) n (%)	Individuals with TF (n=28) n (%)	Individuals with any follicles (n=72) n (%)	Individuals without TF or follicles (n=97) n (%)
<i>Staphylococcus aureus</i>	4 (9)	1 (4)	5 (7)	1 (1)
<i>Staphylococcus aureus</i> ^a (MRSA)	2 (5)	0 (0)	2 (3)	1 (1)
<i>Citrobacter koseri</i> ^b	1 (2)	0 (0)	1 (1)	0 (0)
<i>Proteus mirabilis</i> ^a	1 (2)	0 (0)	1 (1)	0 (0)
<i>Streptococcus pneumoniae</i> ^b	1 (2)	0 (0)	1 (1)	1 (1)
Any bacteria detected	9 (20)	1 (4)	10 (14)	3 (3)

Notes:
a: Swabs from one person cultured *Citrobacter koseri* and *Proteus mirabilis* from the right eye and *Staphylococcus aureus* (MRSA) from the left eye.
b: One person tested positive in both eyes for *Streptococcus pneumoniae*.

Figure 1: Recruitment and results flow diagram, Torres Strait Islands, November 2017.



* One or more follicles present on the upper tarsus but fewer than five
 * One participant did not tolerate collection of specimens for bacterial culture in either eye
 ^ One participant did not tolerate collection of specimen for bacterial culture in one eye

by PCR makes other unidentified viral or allergic causes the more likely precipitants for the follicular conjunctivitis consistent with TF found. Our results resemble those reported in the Melanesian nations of PNG, Solomon Islands, and Vanuatu where the prevalence of TF is high in children, but ocular *C. trachomatis* infection is uncommon and TF is rarely seen in adults.²⁹⁻³² Follow-up surveys in the Solomon Islands found a range of non-chlamydial pathogens detected in individuals with TF but, as with our study, a single dominant aetiology to explain prevalent TF was unable to be identified.³³ Future options for work in the Torres Strait could include using metagenomic deep sequencing for the identification of unexpected pathogens.

In recent years, there has been an increasing body of literature investigating the added value of serological testing to inform trachoma programmatic decision making.³⁴⁻⁴⁰ The protein Pgp3 has been shown to be a specific marker of prior *C. trachomatis* infection and measurement of antibodies against Pgp3 can provide valuable information about the intensity of *C. trachomatis* transmission over time.^{15,41,42} While assessment of anti-Pgp3 antibody levels was outside the scope of this project, its use should be considered in future research activities.

In Australia, trachoma screening occurs in the context of colonisation, dispossession, poverty and continuing marginalisation. We recognise that like many other outreach specialist health services, trachoma screening in remote communities occurs in a siloed manner and, in the era of Close the Gap policy, fails to address inherent racial inequalities. We acknowledge that the current method for trachoma screening and mass drug administration in response to continuing trachoma in remote communities implicitly fails to address the primordial conditions that place communities at risk of trachoma and the consequences of other infections, such as rheumatic heart disease. In this context, there are several communities across Australia where, despite years of repeated MDA, TF prevalence remains constant and elevated. In these communities, our approach of incorporating a more detailed clinical exam by an ophthalmologist and *C. trachomatis* PCR into routine screening may be useful. Without screening using a more specific tool for trachoma, the risk is that communities end up in an ongoing cycle of screening and antibiotic treatment in the absence of

trachoma. Only with such an approach will programs be able to confidently demonstrate the elimination of trachoma in communities where non-chlamydial agents or other aetiologies are the likely cause of persisting follicular conjunctivitis consistent with TF.

Acknowledgements

We are grateful to the Torres Strait Island Regional Council and Torres and Cape Hospital and Health Service for supporting the study and offer a special thanks to the community and participants for their involvement. We are also grateful to the laboratory staff at Pathology Queensland and the Queensland Paediatric Infectious Diseases Laboratory for the analysis of samples. LJW was supported by a National Health and Medical Research Early Career Fellowship (#1142035). This work was performed with funding support from Queensland Health and the Project Agreement on Improving Trachoma Control Services for Indigenous Australians.

References

- World Health Organization. *Weekly Epidemiological Record*. Geneva (CHE): WHO; 2020.
- Thylefors B, Dawson CR, Jones BR, West SK, Taylor HR. A simple system for the assessment of trachoma and its complications. *Bull World Health Organ*. 1987;65(4):6.
- Mabey DCW, Solomon AW, Foster A. Trachoma. *Lancet*. 2003;362(9379):223-9.
- National Trachoma Surveillance and Reporting Unit. *Australian Trachoma Surveillance Report 2019*. Sydney (AUST): University of New South Wales The Kirby Institute; 2019.
- Communicable Diseases Network Australia. *National Guidelines for the Public Health Management of Trachoma*. Australian Department of Health; 2014.
- World Health Organization. *Validation of Elimination of Trachoma as a Public Health Problem*. Geneva (CHE): WHO; 2016.
- Solomon AW, Peeling RW, Foster A, Mabey DC. Diagnosis and assessment of trachoma. *Clin Microbiol Rev*. 2004;17(4):982-1011.
- Solomon AW, Foster A, Mabey DCW. Clinical examination versus Chlamydia trachomatis assays to guide antibiotic use in trachoma control programmes. *Lancet Infect Dis*. 2006;6(1):5-6.
- The Royal Australian College of Ophthalmologists. *National Trachoma and Eye Health Program*. Sydney (AUST): RACO; 1980.
- Arnold A-L, Dunn RA, Members of the National Indigenous Eye Health Survey Team. *National Indigenous Eye Health Survey: Minum Barreng (Tracking Eyes) Full Report*. Melbourne (AUST): University of Melbourne School of Population and Health Indigenous Eye Health Unit; 2009.
- Jones S, Whitehead O, Brian G. Trachoma in Far North Queensland: An example of poor population health practice: Letters to the editor. *Clin Exp Ophthalmol*. 2013;41(6):607-8.
- Hilton AF, Butler M, Cracken CM, Hines R, Ohlrich JG, Swanson M, et al. Field Trip Thursday Island and Torres Strait Islands, November 1982 National Trachoma and Eye Health Programme (Queensland); 1982. Unpublished observations.

- Taylor HR, Fox SS, Xie J, Dunn RA, Arnold A-LMR, Keeffe JE. The prevalence of trachoma in Australia: The National Indigenous Eye Health Survey. *Med J Aust*. 2010;192(5):248.
- Burton M, Hu V, Massae P, Burr S, Chevallier C, Afwamba I, et al. What is causing active trachoma? The role of non-chlamydial bacterial pathogens in a low prevalence setting. *Invest Ophthalmol Vis Sci*. 2011;6(12):6012-17.
- Butcher R, Sokana O, Jack K, Sui L, Russell C, Last A, et al. Clinical signs of trachoma are prevalent among Solomon Islanders who have no persistent markers of prior infection with Chlamydia trachomatis. *Wellcome Open Res*. 2018;3:14.
- Butcher RM, Sokana O, Jack K, Macleod CK, Marks ME, Kalae E, et al. Low prevalence of conjunctival infection with Chlamydia trachomatis in a treatment-naive trachoma-endemic region of the Solomon Islands. *PLoS Negl Trop Dis*. 2016;10(9):e0004863.
- Wright H, McDonnell C, Squire S, Keeffe J, Taylor H. *Trachoma Grading - Self Directed Learning* [CD-ROM]. Melbourne (AUST): Centre for Eye Research Australia; 2007.
- Oberste MS, Peñaranda S, Rogers SL, Henderson E, Nix WA. Comparative evaluation of Taqman real-time PCR and semi-nested VP1 PCR for detection of enteroviruses in clinical specimens. *J Clin Virol*. 2010;49(1):73-4.
- Arden KE, Mackay IM. Newly identified human rhinoviruses: Molecular methods heat up the cold viruses. *Rev Med Virol*. 2010;20(3):156-76.
- Weidmann M, Meyer-König U, Hufert FT. Rapid detection of herpes simplex virus and varicella-zoster virus infections by real-time PCR. *J Clin Microbiol*. 2003;41(4):1565.
- Watzinger F, Suda M, Preuner S, Baumgartinger R, Ebner K, Baskova L, et al. Real-time quantitative PCR assays for detection and monitoring of pathogenic human viruses in immunosuppressed pediatric patients. *J Clin Microbiol*. 2004;42(11):5189-98.
- Northill J, Simmons R. *Molluscum Contagiosum Real-time PCR*. Berkeley (CA): protocols.io; 2017.
- Alsaleh AN, Grimwood K, Sloots TP, Whitley DM. A retrospective performance evaluation of an adenovirus real-time PCR assay. *J Med Virol*. 2014;86(5):795-801.
- Bialasiewicz S, Whitley DM, Buhner-Skinner M, Bautista C, Barker K, Aitken S, et al. A novel gel-based method for self-collection and ambient temperature postal transport of urine for PCR detection of Chlamydia trachomatis. *Sex Transm Infect*. 2008;85(2):102-5.
- European Committee on Antimicrobial Susceptibility Testing. *Breakpoints Tables for Interpretation of MICs and zone Diameters*. Version 9.0. Växjö (SWE): EUCAST; 2019.
- Ishenberg HD. *Clinical Microbiology Procedures Handbook*. Washington (DC): American Society for Microbiology; 1992.
- West SK, Muoz B, Mkocha H, Hsieh Y-H, Lynch MC. Progression of active trachoma to scarring in a cohort of Tanzanian children. *Neuroophthalmology*. 2001;8(2-3):137-44.
- Assaad FA, Maxwell-Lyons F. The use of catalytic models as tools for elucidating the clinical and epidemiological features of trachoma. *Bull World Health Organ*. 1966;34(3):341-55.
- Macleod CK, Butcher R, Javati S, Gwyn S, Jonduo M, Abdad MY, et al. Trachoma, anti-Pgp3 serology and ocular Chlamydia trachomatis infection in Papua New Guinea. *Clin Infect Dis*. 2021;72(3):423-30.
- Butcher R, Handley B, Garae M, Taoaba R, Pickering H, Bong A, et al. Ocular chlamydia trachomatis infection, anti-Pgp3 antibodies and conjunctival scarring in Vanuatu and Tarawa, Kiribati before antibiotic treatment for trachoma. *J Infect*. 2020;80(4):454-61.
- Sokana O, Macleod C, Jack K, Butcher R, Marks M, Willis R, et al. Mapping trachoma in the Solomon Islands: Results of three baseline population-based prevalence surveys conducted with the Global Trachoma Mapping Project. *Ophthalmic Epidemiol*. 2016;23 Suppl 1:15-21.
- Taleo F, Macleod CK, Marks M, Sokana O, Last A, Willis R, et al. Integrated mapping of yaws and trachoma in the five northern-most provinces of Vanuatu. *PLoS Negl Trop Dis*. 2017;11(1):e0005267.

33. Butcher RMR, Sokana O, Jack K, Kalae E, Sui L, Russell C, et al. Active trachoma cases in the Solomon Islands have varied polymicrobial community structures but do not associate with individual non-chlamydial pathogens of the eye. *Front Med (Lausanne)*. 2018;4:251.
34. Migchelsen SJ, Sepulveda N, Martin DL, Cooley G, Gwyn S, Pickering H, et al. Serology reflects a decline in the prevalence of trachoma in two regions of The Gambia. *Sci Rep*. 2017;7(1):15040.
35. Meyer T. Diagnostic procedures to detect chlamydia trachomatis infections. *Microorganisms*. 2016;4(3):25.
36. Martin DL, Bid R, Sandi F, Goodhew EB, Massae PA, Lasway A, et al. Serology for trachoma surveillance after cessation of mass drug administration. *PLoS Negl Trop Dis*. 2015;9(2):e0003555.
37. Cama A, Muller A, Taoaba R, Butcher RMR, Itibita I, Migchelsen SJ, et al. Prevalence of signs of trachoma, ocular chlamydia trachomatis infection and antibodies to Pgp3 in residents of Kiritimati Island, Kiribati. *PLoS Negl Trop Dis*. 2017;11(9):e0005863.
38. West S, Munoz B, Weaver J, Mrango Z, Dize L, Gaydos C, et al. Can we use antibodies to chlamydia trachomatis as a surveillance tool for national trachoma control programs? Results from a district survey. *PLoS Negl Trop Dis*. 2016;10(1):e0004352.
39. Zambrano A, Sharma S, Crowley K, Dize L, Muñoz B, Mishra S, et al. The World Health Organization recommendations for trachoma surveillance, experience in nepal and added benefit of testing for antibodies to chlamydia trachomatis pgp3 protein: NESTS Study. *PLoS Negl Trop Dis*. 2016;10(9):e0005003.
40. Goodhew EB, Priest JW, Moss DM, Zhong G, Munoz B, Mkocho H, et al. CT694 and pgp3 as serological tools for monitoring trachoma programs *PLoS Negl Trop Dis*. 2012;6(11):e1873.
41. Ghaem-Maghami S, Ratti G, Ghaem-Maghami M, Comanducci M, Hay PE, Bailey RL, et al. Mucosal and systemic immune responses to plasmid protein pgp3 in patients with genital and ocular chlamydia trachomatis infection. *Clin Exp Immunol*. 2003;132(3):436-42.
42. Ghaem-Maghami S, Bailey RL, Mabey DC, Hay PE, Mahdi OS, Joof HM, et al. Characterization of B-cell responses to chlamydia trachomatis antigens in humans with trachoma. *Infect Immun*. 1997;65(12):4958.